

7

Melanoma of Unknown Primary

Jeffrey F. Scott • Meg R. Gerstenblith

Department of Dermatology, University Hospitals Cleveland Medical Center and Case Western Reserve University School of Medicine, Cleveland, OH, USA

Author for correspondence: Department of Dermatology, University Hospitals Cleveland Medical Center, Lakeside 3500, 11100 Euclid Avenue, Cleveland, OH 44106, USA. E-mail: Jeffrey.scott@uhhospitals.org

Doi: <http://dx.doi.org/10.15586/codon.noncutaneousmelanoma.2018.ch7>

Abstract: Although the vast majority of melanomas have a known primary site, approximately 3.2% of all melanomas present in distant sites with no known primary site. Melanoma of unknown primary most often presents in lymph nodes, followed by subcutaneous sites, and finally visceral organs. Various hypotheses regarding the origin of melanoma of unknown primary have been proposed, including spontaneous regression of the primary tumor, and the presence of ectopic melanocytes within lymph nodes and visceral organs. Melanoma of unknown primary is less well studied in comparison with melanoma of known primary, but its clinical, molecular, and genetic characteristics have been recently clarified. Specifically, melanoma of unknown primary occurs more often in men in the fourth and fifth decades of life, and shares a similar genetic and molecular signature as cutaneous melanomas arising on skin that is intermittently exposed to the sun, including the back and upper legs. In addition, the prognosis of these patients has also been clarified, and patients with melanoma of unknown primary have improved survival compared to stage-matched patients with melanoma of known primary. This chapter reviews recent advances in the understanding of melanoma of unknown primary, highlighting its genetic and molecular characteristics, epidemiology, prognosis, and treatment, as well as its relationship with melanoma of known primary site.

Key words: Epidemiology; Melanoma of known primary; Melanoma of unknown primary; Metastatic melanoma; Prognosis

In: *Noncutaneous Melanoma*. Jeffrey F. Scott and Meg R. Gerstenblith (Editors), Codon Publications, Brisbane, Australia. ISBN: 978-0-9944381-5-7; Doi: <http://dx.doi.org/10.15586/codon.noncutaneousmelanoma.2018>

Copyright: The Authors.

Licence: This open access article is licenced under Creative Commons Attribution 4.0 International (CC BY 4.0). <https://creativecommons.org/licenses/by-nc/4.0/>

INTRODUCTION

More than 97% of all melanomas are diagnosed with a known primary site, most often involving the skin (1). Less commonly, melanoma can present within the eye or mucous membranes (1). Rarely, melanoma is diagnosed without an obvious primary site, and is referred to as melanoma of unknown primary (MUP). In 1963, Das Gupta originally defined MUP as melanoma discovered in subcutaneous tissue, lymph nodes (LNs), or visceral organs without a cutaneous, ocular, or mucosal primary site (2).

Melanoma of known primary (MKP) is commonly misclassified as MUP. This error stems from a lack of knowledge regarding the melanoma's true primary site, which may result from an incomplete physical examination of all cutaneous, ocular, and mucosal surfaces, or from the history omitting a previously treated or regressed melanoma. Given the inherently problematic nature of accurately defining MUP in clinical practice, Das Gupta also described four exclusion criteria that were intended to aid in the characterization of MUP (Table 1) (2). If any of these exclusion criteria were met, Das Gupta proposed that patients be classified as having MKP rather than MUP (2).

Despite these proposed exclusion criteria, MUP patients described in the literature to date have been heterogeneous, with wide variations in how MUP is

TABLE 1
Exclusion criteria for melanoma of unknown primary, originally proposed by Das Gupta (2)

1. Evidence of previous orbital exenteration or enucleation
2. Evidence of previous skin excision, electrodesiccation, cauterization, or other surgical manipulation of a mole, freckle, birthmark, paronychia, or skin blemish
3. Evidence of metastatic melanoma in a draining lymph node with a scar in the area of skin supplying that lymph node basin
4. Lack of a nonthorough physical examination, including the absence of an ophthalmologic, anal, and genital exam

TABLE 2
Common mutations in melanoma of unknown primary compared to melanoma of known primary

Melanoma of unknown primary	Chronically sun-damaged skin	<i>Melanoma of known primary</i>			
		Intermittently sun-damaged skin	Acral	Mucosal	Ocular
BRAF >	c-KIT >	BRAF >	c-KIT >	c-KIT	GNAQ
NRAS	NRAS >	NRAS	BRAF >		
No c-KIT	BRAF	No c-KIT	NRAS		

defined, and in the interpretation of the exclusion criteria. In fact, in a recent systematic review of MUP, Kamposioras et al. reported that only 16% of peer-reviewed articles and abstracts used the original Das Gupta criteria for the characterization of MUP (3). Most commonly, studies vary in the comprehensiveness of the physical examination that is required before formally diagnosing MUP, including varying degrees of cutaneous, oral, ocular, otolaryngologic, urogenital, and proctoscopic evaluation (3). Particularly for mucosal surfaces, there is no consensus on how thorough an examination of mucosal sites must be before establishing a diagnosis of MUP (3).

HYPOTHESES REGARDING THE ORIGIN OF MUP

Since its original definition, various hypotheses have been put forth to help explain the biological phenomenon of MUP. Metastatic melanoma could theoretically develop synchronously with a subclinical or otherwise unrecognized cutaneous, ocular, or mucosal melanoma (2, 4). This is a less likely explanation for MUP if follow-up times are adequate, however, because the known primary will likely declare itself by the time metastatic disease has developed.

The predominant hypothesis for MUP involves the spontaneous regression of melanoma from a known primary site. The regression theory, first proposed by Smith and Stehlin in 1965, attributes the disappearance of a primary melanoma to spontaneous regression after metastasis has occurred (5). The partial or complete spontaneous regression of melanoma from a known primary site is well documented in the literature, and melanoma accounts for 11% of all cases of spontaneous tumor regression (6–9). However, whereas the partial regression of primary melanoma is fairly common, and is estimated to occur in 9–46% of all melanomas, complete regression is very rare, estimated to occur in only 0.22–0.27% of all melanomas (6, 10–13). Studies reporting on regression specifically in MUP patients reveal that approximately 12.4% of cases are associated with regression either before or after the diagnosis of MUP (6, 11–13).

The spontaneous regression of melanoma is likely immune-mediated, including both cell-mediated and humoral immune mechanisms (10). Regressing melanomas are characterized by increased numbers of tumor-infiltrating lymphocytes, which also confer a favorable prognosis (14, 15). Immune responses to melanoma-associated antigens are also mediated through cytotoxic T-lymphocytes (16). In addition, there is a high prevalence of melanoma-specific antibodies in the serum of MUP patients, and various humoral immune mechanisms, including antibody attachment to cell membranes, cytotoxicity, and tumor destruction, have all been described with cultured melanoma cells *in vitro* (12, 17–22).

Alternatively, MUP could also be explained by the presence of ectopic melanocytes or the differentiation of melanocytes from preexisting pluripotent stem cells within subcutaneous tissue, LNs, or visceral organs (4). Melanocytes are derived from the neural crest, and they migrate along dorsolateral pathways during embryogenesis to reach the skin and hair follicles (23). Melanocytes also migrate to the inner ear, the leptomeninges, and the uveal tract of the eye, which includes the choroid, ciliary body, and iris (23). Occasionally, melanocytes are also found

in other mucosal sites, including the conjunctivae, nasopharyngeal mucosa, esophagus, and anorectal mucosa (23). Regarding LNs, benign nevus cell aggregates and blue nevi have been reported in LNs and other tissues, and, interestingly, melanoma arising from ectopic melanocytes within a LN has been reported (24–27). Thus, melanoma discovered in LNs may originate from the malignant degeneration of neural crest–derived melanocytes that migrated and became arrested in LNs or, alternatively, from benign nevus cells that migrated from the skin to the draining LNs.

In addition, some investigators have questioned whether reports of MUP diagnosed in visceral organs may actually represent primary melanomas arising in unique anatomic locations. For example, the gastrointestinal tract is a common metastatic site for cutaneous melanoma and is also the most widely described visceral site for MUP (3, 28). It has been postulated that cases of gastrointestinal MUP may actually represent cases of primary melanoma derived from melanoblastic cells of the neural crest (28). Melanoblastic cells are known to migrate to the small intestine, predominately the ileum, through the omphalomesenteric canal (28). These melanoblastic cells differentiate into ectopic melanocytes of the gastrointestinal tract, which could theoretically under rare circumstances form primary gastrointestinal melanomas (28). Finally, there is confusion in the literature regarding MUP presenting within the adrenal gland. The adrenal medulla contains neuroendocrine cells derived from the neural crest, and it is thought by some that MUP diagnosed in the adrenal gland should instead be referred to as primary adrenal melanotic malignant pheochromocytoma (29).

GENETICS

The genetic profiles of cutaneous, acral, ocular, and mucosal melanomas differ significantly. Recent studies have examined the genetic profile of MUP (30). Specifically, MUP shares many of the genetic and molecular signatures of melanoma arising from intermittently sun-exposed sites on the skin, including the back and upper legs (Table 2) (31–33). An analysis of 102 MUP patients after therapeutic lymphadenectomy revealed that BRAF and NRAS mutations occurred in 53 and 14% of MUP specimens, respectively (31). Of note, BRAF V600E mutations compromised 93% of all BRAF mutations in this MUP cohort, and no c-KIT mutations were identified (31). Thus, the genotype of MUP most closely resembles that of cutaneous melanoma, specifically the superficial spreading and nodular histological subtypes arising from intermittently sun-damaged skin (33, 34). This genetic signature is distinct from cutaneous melanoma arising from chronically sun-damaged skin, acral skin, and mucosal sites, which are commonly enriched for c-KIT mutations (34). In a separate analysis of 39 MUP patients, mutations in the TERT-promoter were found more commonly in MUP than in mucosal melanoma (66.7% vs. 13.2%, respectively) (35). The presence of TERT-promoter mutations in MUP tumors correlated with a higher percentage of BRAF and NRAS mutations, leading to the hypothesis that TERT-promoter mutations may function as driver mutations in MUP (35).

INCIDENCE AND DEMOGRAPHICS

Likely related to the inherent difficulty in defining MUP, the incidence of MUP is widely reported, ranging from 1.2% to as high as 31% (36–38). Recently, a large systematic review clarified the true incidence of MUP and reported an overall incidence of 3.2%, which remained stable when children and adolescents were excluded from the analysis (3). The wide incidence range previously reported in the literature could also be partly explained by the improving technology of medical imaging, which can lead to enhanced identification of the primary tumor (3). In the above systematic review, the incidence of MUP before the modern computed tomography era (3) in 1980 was 5.1%, as compared to 2.7% after 1980 (3).

The peak incidence of MUP occurs in the fourth and fifth decades of life, comparable to cutaneous melanoma, but earlier than mucosal and ocular melanoma (1, 39). The younger age of MUP peak incidence may be attributed to the robust immune responses of younger patients, resulting in a higher rate of primary site regression (3). Moreover, MUP occurs twice as often in men as in women, and this has been attributed to epidemiologic factors related to an increased likelihood for primary site regression (3). For example, men may be more likely to ignore a primary cutaneous melanoma until after it completely regresses and later presents as metastatic disease, and men are also more prone to developing melanoma in anatomic sites where regression may be more likely to occur, including the back and scalp (3).

METASTATIC SITES

MUP is most commonly diagnosed in LNs (40–60% of all cases) and has been reported to involve the axillary, cervical, inguinal, and parotid LNs in 52.2, 32.7, 28.3, and 2.6% of cases, respectively (3, 13, 40). In men, MUP most commonly presents in axillary and cervical LNs, whereas in women it is most likely to present in inguinal LNs (3). The higher incidence of inguinal LN involvement in women compared to men has been attributed to the higher incidence of leg and anogenital melanoma in women (4).

After the LNs, MUP is diagnosed most commonly in subcutaneous sites (approximately 30% of cases) and is least commonly diagnosed in visceral organs (approximately 20% of cases) (3, 13). In the recent systematic review of MUP, 5.1% of patients presented with subcutaneous involvement, 4.9% with single or multiple visceral sites, and 0.7% with osseous deposits (3). A multitude of visceral sites are reported with MUP, including the brain, parotid gland, heart, mediastinum, lung, breast, liver, common bile duct, small and large intestine, kidney, adrenal gland, prostate, bone, bone marrow, and muscle (29, 41–65). As expected, varying clinical presentations of visceral disease are described in the literature depending on the involved organ (Table 3) (46, 49, 59, 66–72). MUP can also present as a paraneoplastic syndrome, reported as retinopathy, systemic vasculitis, inflammatory demyelinating polyneuropathy, diffuse vitiligo-like depigmentation, and Gorham-Stout syndrome, or vanishing bone disease (73–78). Vitiligo-like depigmentation appears to be a fairly common presentation of widespread metastatic disease and can precede the discovery of MUP by up to 18 months (76, 79, 80).

TABLE 3**Varied clinical presentations reported for melanoma of unknown primary (46, 49, 59, 66–72)**

Involved visceral organ	Clinical presentation
Colon (47, 50, 53, 66, 67)	Intestinal obstruction Intussusception Gastrointestinal bleeding Bowel perforation
Kidney (54)	Hematuria
Heart (59, 69)	Pericardial effusion Heart failure
Liver (46, 68)	Hepatosplenomegaly Fulminant liver failure
Sacrum (70)	Radiculopathy
Brain (55, 72)	Acute meningitis Seizures
Bone marrow (49, 62)	Thrombocytopenia
Seminal vesicles (71)	Hemospermia

A few special considerations regarding visceral involvement should be emphasized. First, the original primary melanoma can become clinically evident after the diagnosis of MUP. For example, Kumar et al. reported the case of a 56-year-old woman with MUP diagnosed in a left axillary LN who presented with a primary cutaneous melanoma of the left finger 18 months after the original MUP diagnosis (81). Second, MUP can present with varied histological appearances, which can often complicate the pathologic diagnosis, and underscore the importance of immunohistochemistry in making a diagnosis of MUP. MUP has been described as a signet-ring cell neoplasm with abundant intermediate filaments that was only recognized as a melanocyte neoplasm when it stained positive for vimentin, S-100, and HMB-45 (82). Similarly, Adler et al. described the case of an angiomatoid melanoma mimicking a vascular malignancy, characterized histologically as a spindle cell tumor with numerous cavernous, erythrocyte-filled spaces, and only scant melanin pigmentation (83).

STAGING AND PROGNOSTIC FACTORS

The prognostic factors of patients with MUP are similar to those of MKP with the same clinical stage at presentation (84–86). However, until recently, no uniform staging guidelines existed for MUP (8, 87, 88). In 2009, the American Joint Committee on Cancer (AJCC) melanoma staging system classified MUP as stage III disease if there were LN or subcutaneous involvement at initial presentation, and as stage IV disease if there were visceral involvement (89). Serum S100 protein and positron emission tomography (PET) are recommended for baseline staging

of MUP patients (90). In one study, serum S100 protein was elevated in 35% of MUP patients, and PET scans detected occult distant metastases in 86% of MUP patients (90). In addition, distant metastases were associated with significantly higher serum S100 proteins levels, suggesting that serum S100 protein may be a sensitive and specific marker to detect occult distant metastatic disease in MUP patients (90).

Similar to MKP, the patient's age, AJCC stage, lactate dehydrogenase level, and number of metastases at diagnosis are all independent prognostic factors for MUP (91). Furthermore, in multivariate analyses stratified by AJCC stage, in-transit metastases and number of involved LNs are independent prognostic factors for stage III disease, and age and lactate dehydrogenase level at diagnosis are independent prognostic factors for stage IV disease (91). Additional positive prognostic factors for MUP include evidence of tumor regression, fewer numbers of involved LNs, and prompt surgical treatment within 3 months (3, 86, 91–93). Moreover, four studies reported a better prognosis for younger patients, but the effect of gender on prognosis is yet to be fully elucidated (3, 36, 91, 94, 95). Negative prognostic factors include the involvement of cervical LNs, extracapsular extension, and the presence of in-transit metastases (86, 88, 91, 96, 97). Ultimately, LN involvement was identified as the most important prognostic factor in MUP (97). Specifically considering only stage IV disease, an increased number of metastatic sites and lactate dehydrogenase at presentation were both associated with significantly worse outcomes (91).

Concerning mutational status, the presence of BRAS, NRAS, and TERT-promoter mutations do not appear to have a significant prognostic impact, as there is no correlation between mutational status and overall survival (OS) for MUP patients (31, 33). Interestingly, MUP patients with vitiligo may have improved survival (13, 98). For example, vitiligo was diagnosed in 5 of 88 MUP patients in one cohort, and the presence of vitiligo was associated with a favorable prognosis (13). Another study described prolonged survival associated with the development of vitiligo 6 years after the diagnosis of MUP in axillary LNs (99). In this case report, there was no recurrence of melanoma 10 years after surgical resection of the involved LNs (99).

SURVIVAL

Median OS ranges from 24 months to 127 months for MUP patients presenting with LN disease (AJCC stage III), with 5- and 10-year OS ranging from 28.6 to 75.6%, and 18.8 to 62.9%, respectively (3, 39). The OS of stage III MUP is significantly better than MUP patients with visceral stage (AJCC stage IV), with median OS ranging from 3 to 13 months, 5-year OS ranging from 5.9 to 18%, and no 10-year survivors (3, 39). In a systematic review of MUP, seven studies demonstrated a significantly better prognosis for nodal MUP, compared to subcutaneous or visceral MUP (1, 8, 11, 91, 95, 100, 101). Regarding the effect of surgical management on survival, prompt radical neck LN dissection led to improved survival in three studies, while modified radical neck LN dissection led to improved survival in just one study (1, 8, 102, 103). However, the prognostic advantage of modified versus radical neck LN dissection could not be

conclusively determined in the systematic review (3). Similar to stage III MKP, non-surgical management of stage III MUP is associated with worse survival compared to surgical management (3). Some investigators suggest that surgery not only decreases the overall tumor burden but also decreases the degree of immunosuppression, allowing anti-tumor immunity to develop (3).

Survival of MUP compared to MKP patients

Several studies attempting to compare survival differences between MUP and MKP patients utilizing matched patients and historical controls have revealed mixed results. As early as 1998, Vijuk and Coates reported a median survival of 233 days for MUP patients, compared to 176 days for MKP patients (104). Similarly, Prens et al. examined outcomes of MUP patients after therapeutic neck LN dissections and found a trend for improved survival in MUP compared to MKP patients with 5-year OS of 40 and 27%, respectively (105). More recently, Weide et al. also reported improved OS for MUP patients compared to MKP patients with LN involvement (median OS 65 months vs. 24 months, respectively) (96, 97). Regarding stage IV disease, a retrospective analysis of 534 patients with stage IV MUP and a median follow-up of 10.4 months revealed that MUP patients had a similar survival as cutaneous melanoma and uveal melanoma from the time of first distant metastasis but significantly better survival than mucosal melanoma (106).

A statistically significant survival difference between MUP and MKP patients has been demonstrated in only a handful of published studies (3). Lee et al. reported a significantly higher 5-year OS for MUP patients compared to MKP patients when matched for nodal metastases, site of metastatic disease, and number of metastatic sites (36, 39). Matching stage III patients based on four additional covariates, including age, sex, nodal tumor burden, and decade of diagnosis, also revealed a significantly higher median OS for MUP compared to MKP patients (164 months vs. 34 months, respectively) (39).

In an attempt to clarify the prognosis of MUP compared to MKP patients, Bae et al. recently conducted a meta-analysis of all studies reporting on survival to date, and reported better OS for stage III MUP patients compared to MKP patients (hazard ratio 0.83, 95% confidence interval 0.73–0.96, $P = 0.01$) and stage IV MUP patients compared to MKP patients (hazard ratio 0.85, 95% confidence interval 0.75–0.96, $P = 0.08$) (107). Subgroup analyses also showed that MUP patients with nodal disease only had improved OS (hazard ratio 0.82, 95% CI 0.71–0.95) and disease-free survival compared to MKP patients (hazard ratio 0.84, 95% CI 0.70–1.00) (107). The improved survival of stage III and stage IV patients MUP compared to MKP patients is particularly striking given that lead-time bias should inherently favor a survival benefit for MKP patients because the presence of a known primary would likely lead to an earlier diagnosis of each disease stage.

DIAGNOSIS

A thorough evaluation, including ophthalmologic and anogenital exams, is required when melanoma is diagnosed within the subcutaneous fat, LNs, or visceral organs

without an obvious primary source. However, the exact type of work-up that is recommended for MUP patients after a complete physical examination is controversial (Figure 1). In one study of 103 MUP patients, Tos et al. found that 84% of patients were examined by an ophthalmologist, 82% by an otorhinolaryngologist, and 89% by a gynecologist (108). Moreover, 92% of MUP patients had additional gastrointestinal imaging performed, including sigmoidoscopy and proctoscopy (108). Of the additional referrals and evaluations performed in this particular study, the only primary site discovered was that of an undiagnosed choroidal melanoma (108). Based on these findings, this group recommended a detailed history, physical examination, histopathologic review, and CT and/or PET for accurate staging for all new MUP patients but suggested that additional subspecialty referrals and specialized screenings may be redundant (108).

Similarly, a worldwide survey of 119 providers in 47 countries analyzed the clinical and laboratory work-up required for MUP patients after a thorough history and physical examination (109). Half of all responders specifically assessed for the presence of vitiligo that may help explain regression of the primary site (109). Three-quarters of all responders applied the same protocols for MUP patients as AJCC stage-matched MKP patients (109). In addition, all responders asked about the history of previous skin excisions, and 81% reviewed histopathologic slides from prior biopsies (109). Specifically, histopathologic review by an experienced pathologist is essential, as MUP can mimic other spindle cell neoplasms. For example, MUP of the parotid gland mimicked an interdigitating dendritic cell sarcoma, and ultimately required immunohistochemical staining to accurately

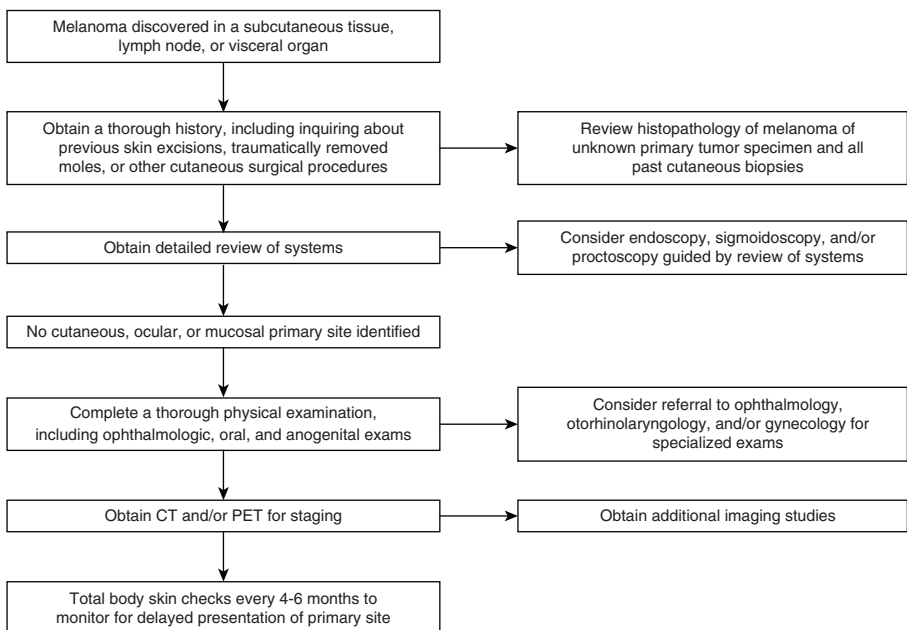


Figure 1 Work-up for newly diagnosed melanoma of unknown primary.

identify the melanocytic origin of the tumor (110). In another case, hilar and mediastinal masses were initially highly suggestive of a primary lung cancer radiographically but were ultimately discovered to be S100-negative MUP after histological analysis (111).

In addition, long-term follow-up is essential, as the occult primary can become clinically apparent over 5 years after the original diagnosis of MUP. In one case report of MUP diagnosed in the liver and treated with chemotherapy and radiation, the most likely primary, a nasopharyngeal mucosal melanoma, only became clinically apparent 6 years after the original MUP diagnosis because of new onset epistaxis (112). In another case report of MUP diagnosed in the small intestine, the most likely primary became clinically apparent on the scalp 15 years after the original MUP diagnosis (113). These delayed primary site presentations may have resulted from incomplete physical examinations at the time of initial MUP diagnosis, or they could relate to alterations in the patients' immune responses, resulting in growth of the primary tumor to the point of becoming clinically apparent.

Molecular profiling, imaging, autoantibodies, and dermoscopy can be used for the accurate diagnosis of MUP (114, 115). In the above survey study, 32% of respondents also screened MUP tumor specimens for BRAF, c-KIT, and GNAQ mutations, and the most common imaging modalities utilized were CT and/or PET (109). Furthermore, transient receptor potential melastatin 1 (TRPM1) autoantibodies may be useful in the work-up of MUP (116). Dalal et al. described a patient with bilateral intraocular inflammation and retinal hemorrhage concerning for melanoma-associated retinopathy whose initial work-up for melanoma was unrevealing (116). Subsequently, the patient was found to have positive TRPM1 autoantibodies, which then prompted additional imaging that revealed an occult MUP involving an axillary LN (116). Finally, various groups have suggested that dermoscopy should be used to systematically narrow the field of potential candidate pigmented lesions for biopsy, and to identify subtly atypical pigmented lesions in order to diagnose an occult primary melanoma (115, 117).

MANAGEMENT

Numerous case series have supported the consensus that MUP patients should be treated with early aggressive surgical management in a similar fashion as MKP patients (6, 8, 100, 102, 118, 119). Most recently, a cohort of 78 MUP patients with LN or subcutaneous disease treated with regional lymphadenectomy or wide local excision further supports these early treatment recommendations (120). Although the local recurrence rate of subcutaneous disease after wide local excision with one to two centimeter margins was relatively high at 65%, the authors concluded that wide local excision still remains the best treatment option for subcutaneous disease (120). In contrast, the significantly lower local recurrence rate of 11% for LN disease after regional LN dissection substantiates its use as the standard of care for MUP with LN involvement (120).

Moreover, regional lymphadenectomy for palpable LN metastases was associated with significantly improved 5-year OS for stage III MUP patients compared to MKP patients (39). When patients were matched based on age, sex, nodal

tumor burden, and decade of diagnosis, the median OS was 164 months for MUP patients compared to 34 months for MKP patients (39). Similar findings were confirmed in a separate cohort of MUP patients, which also demonstrated improved disease-free, distant metastases-free survival, and melanoma-specific survival for MUP patients compared to MKP patients after therapeutic LN dissection (121). Extranodal extension, greater than three positive LNs, and adjuvant radiotherapy were all independent predictors of reduced disease-free and melanoma-specific survival in MUP patients (121). Thus, the absence of a primary site should not preclude aggressive surgical management with regional lymphadenectomy in stage III MUP patients, and these patients should also be considered for adjuvant therapies traditionally aimed at stage III MKP patients (105, 122, 123).

These findings were confirmed in the systematic review of MUP performed by Kamposioras et al. (3). Wide local excision or LN dissection, either radical or modified, combined with parotidectomy, if necessary, is the current standard of care for surgical management of stage III MUP (3). Stage IV MUP also warrants aggressive therapy, and it should be treated similarly to stage IV MKP with a combination of surgery, chemotherapy, immunotherapy, and radiotherapy, as the median OS and 5-year OS for stage IV MUP is significantly higher than stage IV MKP when matched for the site of metastatic involvement (36).

CONCLUSION

MUP, defined by the presence of melanoma in distant subcutaneous sites, LNs, or visceral organs without an obvious cutaneous, ocular, or mucosal primary site, is a well-characterized entity in the literature. It comprises 3.2% of all new melanoma diagnoses and occurs more commonly in men with a peak incidence in the fourth and fifth decades of life. LN involvement occurs more often than subcutaneous or visceral disease and most commonly affects the axillary LNs. Furthermore, involvement of a wide variety of visceral organs has been reported with MUP, and the possibility of primary noncutaneous melanomas occurring as a result of the malignant degeneration of ectopic melanocytes present in visceral organs, including the gastrointestinal tract, should be considered.

MUP should be classified as AJCC stage III disease if it is diagnosed in LNs, or as subcutaneous tissue at initial presentation, or as AJCC stage IV disease if it is diagnosed in visceral organs. MUP patients have better prognoses and improved OS compared to stage-matched MKP patients, suggesting that immunologically mediated primary site regression may be the common underlying mechanism explaining the biological phenomenon of MUP. Given their improved survival, patients with stage III MUP should be treated with wide local excision for subcutaneous disease, and modified or radical LN resection for LN disease, and these patients should be offered enrollment in clinical trials as well as similar adjuvant therapy as stage III MKP patients. Finally, patients with stage IV MUP should be treated aggressively and similarly to patients with stage IV MKP, with combination of surgery, chemotherapy, immunotherapy, and radiotherapy.

Acknowledgments: This work was supported by grants from the Char and Chuck Fowler Family Foundation and the Dermatology Foundation.

Conflict of interest: The authors declare no potential conflict of interest with respect to research, authorship, and/or publication of this article.

Copyright and permission statement: To the best of our knowledge, the materials included in this chapter do not violate copyright laws. All original sources have been appropriately acknowledged and/or referenced. Where relevant, appropriate permissions have been obtained from the original copyright holder(s).

REFERENCES

1. Chang AE, Karnell LH, Menck HR. The National Cancer Data Base report on cutaneous and noncutaneous melanoma: A summary of 84,836 cases from the past decade. *The American College of Surgeons Commission on Cancer and the American Cancer Society. Cancer.* 1998;83(8):1664–78. [http://dx.doi.org/10.1002/\(SICI\)1097-0142\(19981015\)83:8%3C1664::AID-CNCR23%3E3.0.CO;2-G](http://dx.doi.org/10.1002/(SICI)1097-0142(19981015)83:8%3C1664::AID-CNCR23%3E3.0.CO;2-G)
2. Dasgupta T, Bowden L, Berg JW. Malignant melanoma of unknown primary origin. *Surg Gynecol Obstet.* 1963;117:341–5.
3. Kamposioras K, Pentheroudakis G, Pectasides D, Pavlidis N. Malignant melanoma of unknown primary site. To make the long story short. A systematic review of the literature. *Crit Rev Oncol Hematol.* 2011;78(2):112–26. <http://dx.doi.org/10.1016/j.critrevonc.2010.04.007>
4. Bankar S, Patkar S, Desai S, Shrikhande SV. Unusual presentation of melanoma of unknown primary origin: A case report and review of literature. *J Cancer Res Ther.* 2015;11(4):1025. <http://dx.doi.org/10.4103/0973-1482.148680>
5. Smith JL Jr., Stehlin JS Jr. Spontaneous regression of primary malignant melanomas with regional metastases. *Cancer.* 1965;18(11):1399–415. [http://dx.doi.org/10.1002/1097-0142\(196511\)18:11%3C1399::AID-CNCR2820181104%3E3.0.CO;2-R](http://dx.doi.org/10.1002/1097-0142(196511)18:11%3C1399::AID-CNCR2820181104%3E3.0.CO;2-R)
6. Panagopoulos E, Murray D. Metastatic malignant melanoma of unknown primary origin: A study of 30 cases. *J Surg Oncol.* 1983;23(1):8–10. <http://dx.doi.org/10.1002/jso.2930230104>
7. Muchmore JH, Kremenz ET, Carter RD, Sutherland CM, Mendoza EA. Isolated perfusion of extremities for metastatic melanoma from an unknown primary lesion. *S Med J.* 1986;79(3):288–90. <http://dx.doi.org/10.1097/00007611-198603000-00007>
8. Lopez R, Holyoke ED, Moore RH, Karakousis CP. Malignant melanoma with unknown primary site. *J Surg Oncol.* 1982;19(3):151–4. <http://dx.doi.org/10.1002/jso.2930190308>
9. Giuliano AE, Moseley HS, Morton DL. Clinical aspects of unknown primary melanoma. *Ann Surg.* 1980;191(1):98–104. <http://dx.doi.org/10.1097/00000658-198001000-00018>
10. Blessing K, McLaren KM. Histological regression in primary cutaneous melanoma: Recognition, prevalence and significance. *Histopathology.* 1992;20(4):315–22. <http://dx.doi.org/10.1111/j.1365-2559.1992.tb00988.x>
11. Anbari KK, Schuchter LM, Bucky LP, Mick R, Synnestvedt M, Guerry Dt, et al. Melanoma of unknown primary site: Presentation, treatment, and prognosis—A single institution study. University of Pennsylvania Pigmented Lesion Study Group. *Cancer.* 1997;79(9):1816–21. [http://dx.doi.org/10.1002/\(SICI\)1097-0142\(19970501\)79:9%3C1816::AID-CNCR26%3E3.0.CO;2-#](http://dx.doi.org/10.1002/(SICI)1097-0142(19970501)79:9%3C1816::AID-CNCR26%3E3.0.CO;2-#)
12. Giuliano AE, Moseley HS, Irie RF, Golub SH, Morton DL. Immunologic aspects of unknown primary melanoma. *Surgery.* 1980;87(1):101–5.
13. Savoia P, Fava P, Osella-Abate S, Nardo T, Comessatti A, Quaglino P, et al. Melanoma of unknown primary site: A 33-year experience at the Turin Melanoma Centre. *Melanoma Res.* 2010;20(3):227–32. <http://dx.doi.org/10.1097/CMR.0b013e328333bc04>
14. Clemente CG, Mihm MC Jr., Bufalino R, Zurrida S, Collini P, Cascinelli N. Prognostic value of tumor infiltrating lymphocytes in the vertical growth phase of primary cutaneous melanoma. *Cancer.* 1996;77(7):1303–10. [http://dx.doi.org/10.1002/\(SICI\)1097-0142\(19960401\)77:7%3C1303::AID-CNCR12%3E3.0.CO;2-5](http://dx.doi.org/10.1002/(SICI)1097-0142(19960401)77:7%3C1303::AID-CNCR12%3E3.0.CO;2-5)

15. Haanen JB, Baars A, Gomez R, Weder P, Smits M, de Gruijl TD, et al. Melanoma-specific tumor-infiltrating lymphocytes but not circulating melanoma-specific T cells may predict survival in resected advanced-stage melanoma patients. *Cancer Immunol Immunother*. 2006;55(4):451–8. <http://dx.doi.org/10.1007/s00262-005-0018-5>
16. Saleh FH, Crotty KA, Hersey P, Menzies SW. Primary melanoma tumour regression associated with an immune response to the tumour-associated antigen melan-A/MART-1. *Int J Cancer*. 2001;94(4):551–7. <http://dx.doi.org/10.1002/ijc.1491>
17. Hsueh EC, Gupta RK, Yee R, Leopoldo ZC, Qi K, Morton DL. Does endogenous immune response determine the outcome of surgical therapy for metastatic melanoma? *Ann Surg Oncol*. 2000;7(3):232–8. <http://dx.doi.org/10.1007/BF02523659>
18. Litvak DA, Gupta RK, Yee R, Wanek LA, Ye W, Morton DL. Endogenous immune response to early- and intermediate-stage melanoma is correlated with outcomes and is independent of locoregional relapse and standard prognostic factors. *J Am Coll Surg*. 2004;198(1):27–35. <http://dx.doi.org/10.1016/j.jamcollsurg.2003.08.012>
19. Bodurtha AJ, Chee DO, Laucius JF, Mastrangelo MJ, Prehn RT. Clinical and immunological significance of human melanoma cytotoxic antibody. *Cancer Res*. 1975;35(1):189–93. <http://dx.doi.org/10.1097/00006534-197505000-00064>
20. Canevari S, Fossati G, Della Porta G, Balzarini GP. Humoral cytotoxicity in melanoma patients and its correlation with the extent and course of the disease. *Int J Cancer*. 1975;16(5):722–9. <http://dx.doi.org/10.1002/ijc.2910160504>
21. Lewis MG, Ikonopisov RL, Nairn RC, Phillips TM, Fairley GH, Bodenham DC, et al. Tumour-specific antibodies in human malignant melanoma and their relationship to the extent of the disease. *Br Med J*. 1969;3(5670):547–52. <http://dx.doi.org/10.1136/bmj.3.5670.547>
22. Morton DL, Malmgren RA, Holmes EC, Ketcham AS. Demonstration of antibodies against human malignant melanoma by immunofluorescence. *Surgery*. 1968;64(1):233–40.
23. Hussein MR. Extracutaneous malignant melanomas. *Cancer Invest*. 2008;26(5):516–34. <http://dx.doi.org/10.1080/07357900701781762>
24. Shenoy BV, Fort L 3rd, Benjamin SP. Malignant melanoma primary in lymph node. The case of the missing link. *Am J Surg Pathol*. 1987;11(2):140–6. <http://dx.doi.org/10.1097/00000478-198702000-00008>
25. Sterchi JM, Muss HB, Weidner N. Cellular blue nevus simulating metastatic melanoma: Report of an unusually large lesion associated with nevus-cell aggregates in regional lymph nodes. *J Surg Oncol*. 1987;36(1):71–5. <http://dx.doi.org/10.1002/jso.2930360117>
26. Ridolfi RL, Rosen PP, Thaler H. Nevus cell aggregates associated with lymph nodes: Estimated frequency and clinical significance. *Cancer*. 1977;39(1):164–71. [http://dx.doi.org/10.1002/1097-0142\(197701\)39:1%3C164::AID-CNCR2820390127%3E3.0.CO;2-T](http://dx.doi.org/10.1002/1097-0142(197701)39:1%3C164::AID-CNCR2820390127%3E3.0.CO;2-T)
27. Mancini L, Gubinelli M, Fortunato C, Carella R. Blue nevus of the lymph node capsule. Report of a case. *Pathologica*. 1992;84(1092):547–50.
28. Manouras A, Genetzakis M, Lagoudianakis E, Markogiannakis H, Papadima A, Kafiri G, et al. Malignant gastrointestinal melanomas of unknown origin: Should it be considered primary? *World J Gastroenterol*. 2007;13(29):4027–9. <http://dx.doi.org/10.3748/wjg.v13.i29.4027>
29. Dao AH, Page DL, Reynolds VH, Adkins RB Jr. Primary malignant melanoma of the adrenal gland. A report of two cases and review of the literature. *Am Surg*. 1990;56(4):199–203.
30. Dutton-Regester K, Kakavand H, Aoude LG, Stark MS, Gartside MG, Johansson P, et al. Melanomas of unknown primary have a mutation profile consistent with cutaneous sun-exposed melanoma. *Pigment Cell Melanoma Res*. 2013;26(6):852–60. <http://dx.doi.org/10.1111/pcmr.12153>
31. Gos A, Jurkowska M, van Akkooi A, Robert C, Kosela-Paterczyk H, Koljenovic S, et al. Molecular characterization and patient outcome of melanoma nodal metastases and an unknown primary site. *Ann Surg Oncol*. 2014;21(13):4317–23. <http://dx.doi.org/10.1245/s10434-014-3799-y>
32. Baiter M, Schuler G, Hartmann A, Schneider-Stock R, Heinzerling L. Pathogenetic implications of BRAF mutation distribution in stage IV melanoma patients. *Dermatology*. 2015;231(2):127–33. <http://dx.doi.org/10.1159/000381849>
33. Egberts F, Bergner I, Kruger S, Haag J, Behrens HM, Hauschild A, et al. Metastatic melanoma of unknown primary resembles the genotype of cutaneous melanomas. *Ann Oncol*. 2014;25(1):246–50. <http://dx.doi.org/10.1093/annonc/mdt411>

34. Genomic classification of cutaneous melanoma. *Cell*. 2015;161(7):1681–96. <http://dx.doi.org/10.1016/j.cell.2015.05.044>
35. Egberts F, Kruger S, Behrens HM, Bergner I, Papaspyrou G, Werner JA, et al. Melanoma of unknown primary frequently harbor TERT-promoter mutations. *Melanoma Res*. 2014;24(2):131–6. <http://dx.doi.org/10.1097/CMR.0000000000000048>
36. Lee CC, Faries MB, Wanek LA, Morton DL. Improved survival for stage IV melanoma from an unknown primary site. *J Clin Oncol*. 2009;27(21):3489–95. <http://dx.doi.org/10.1200/JCO.2008.18.9845>
37. Sutherland CM, Chmiel JS, Bieligg S, Henson DE, Winchester DP. Patient characteristics, treatment, and outcome of unknown primary melanoma in the United States for the years 1981 and 1987. *Am Surg*. 1996;62(5):400–6.
38. Wang BY, Lawson W, Robinson RA, Perez-Ordóñez B, Brandwein M. Malignant melanomas of the parotid: Comparison of survival for patients with metastases from known vs unknown primary tumor sites. *Arch Otolaryngol Head Neck Surg*. 1999;125(6):635–9. <http://dx.doi.org/10.1001/archotol.125.6.635>
39. Lee CC, Faries MB, Wanek LA, Morton DL. Improved survival after lymphadenectomy for nodal metastasis from an unknown primary melanoma. *J Clin Oncol*. 2008;26(4):535–41. <http://dx.doi.org/10.1200/JCO.2007.14.0285>
40. Eltawansy SA, Panasiti R, Hasanien S, Lourdasamy D, Sharon D. Metastatic malignant melanoma of the inguinal lymph node with unknown primary lesion. *Case Rep Med*. 2015;2015:879460. <http://dx.doi.org/10.1155/2015/879460>
41. Scott JF, Thompson CL, Vyas R, Honda K, Zender C, Rezaee R, et al. Parotid melanoma of unknown primary. *J Cancer Res Clin Oncol*. 2016;142(7):1529–37. <http://dx.doi.org/10.1007/s00432-016-2156-x>
42. Tosev G, Kuru TH, Huber J, Freier G, Bergmann F, Hassel JC, et al. Primary melanoma of the prostate: Case report and review of the literature. *BMC Urol*. 2015;15:68. <http://dx.doi.org/10.1186/s12894-015-0052-3>
43. Shenoy AS, Desai HM, Kavishwar VS, Savant HV. Metastatic malignant melanoma in a young adult with unknown primary. *Indian J Cancer*. 2015;52(3):446–7. <http://dx.doi.org/10.4103/0019-509X.176748>
44. Pujani M, Hassan MJ, Jetley S, Raina PK, Kumar M. Malignant melanoma presenting as a mediastinal malignant melanoma presenting as a mediastinal unknown primary origin? *Turk Patoloji Derg*. 2017;33(2):168–70. <http://dx.doi.org/10.5146/tjpath.2014.01290>
45. Tanaka K, Tomita H, Hisamatsu K, Hatano Y, Yoshida K, Hara A. Acute liver failure associated with diffuse hepatic infiltration of malignant melanoma of unknown primary origin. *Intern Med*. 2015;54(11):1361–4. <http://dx.doi.org/10.2169/internalmedicine.54.3428>
46. Tanaka M, Watanabe S, Masaki T, Kurokohchi K, Kinekawa F, Inoue H, et al. Fulminant hepatic failure caused by malignant melanoma of unknown primary origin. *J Gastroenterol*. 2004;39(8):804–6. <http://dx.doi.org/10.1007/s00535-003-1379-1>
47. Stagnitti F, Orsini S, Martellucci A, Tudisco A, Avallone M, Aiuti F, et al. Small bowel intussusception due to metastatic melanoma of unknown primary site. Case report. *G Chir*. 2014;35(9–10):246–9. <http://dx.doi.org/10.11138/gchir/2014.35.9.246>
48. Blanco R, Rodríguez Villar D, Fernández-Pello S, Baldissera JV, Díaz B, Venta V, et al. Massive bilateral adrenal metastatic melanoma of occult origin: A case report. *Anal Quant Cytopathol Histopathol*. 2014;36(1):51–4.
49. Suzuki T, Kusumoto S, Iida S, Tada T, Mori F. Amelanotic malignant melanoma of unknown primary origin metastasizing to the bone marrow: A case report and review of the literature. *Intern Med*. 2014;53(4):325–8. <http://dx.doi.org/10.2169/internalmedicine.53.1412>
50. Reddy P, Walker C, Afonso B. A rare case of metastatic malignant melanoma to the colon from an unknown primary. *Case Rep Gastrointest Med*. 2014;2014:312902. <http://dx.doi.org/10.1155/2014/312902>
51. Bostanci O, Kartal K, Battal M. Liver metastases of unknown primary: Malignant melanoma. *Case Rep Hepatol*. 2014;2014:131708. <http://dx.doi.org/10.1155/2014/131708>
52. Ejaz S, Shawa H, Henderson SA, Habra MA. Melanoma of unknown primary origin presenting as a rapidly enlarging adrenal mass. *BMJ Case Rep*. 2013;2013:pil: bcr2013009727. <https://doi.org/10.1136/bcr-2013-009727>

53. Hedayati AA, Bandurski J, Lewandowski A. Bifocal metastasis of melanoma to the small intestine from an unknown primary with intestinal obstruction—Case report. *Contemp Oncol (Pozn)*. 2013;17(3):317–20. <http://dx.doi.org/10.5114/wo.2013.35285>
54. Dhandha M, Chu MB, Richart JM. Coexistent metastatic melanoma of the kidney with unknown primary and renal cell carcinoma. *BMJ Case Rep*. 2012;2012:pil: bcr2012007286. <https://doi.org/10.1136/bcr-2012-007286>
55. Skarbez K, Fanciullo L. Metastatic melanoma from unknown primary presenting as dorsal midbrain syndrome. *Optom VisSci*. 2012;89(12):e112–17. <http://dx.doi.org/10.1097/OPX.0b013e3182771698>
56. Patel RB, Vasava NC, Gandhi MB. Acute small bowel obstruction due to intussusception of malignant amelanotic melanoma of the small intestine. *BMJ Case Rep*. 2012;2012:pil: bcr2012006352. <https://doi.org/10.1136/bcr-2012-006352>
57. Yeniova O, Altunbas A, Ersoy O, Aydinli M, Bayraktar Y. Metastatic liver malignant melanoma of unknown origin. *Turk J Gastroenterol*. 2012;23(4):420–1. <http://dx.doi.org/10.4318/tjg.2012.0375>
58. Christopoulos P, Doulias T, Koutelidakis I, Papaziogas B. Stage IV malignant melanoma of unknown primary site in a young man. *BMJ Case Rep*. 2012;2012:pil: bcr2012006283. <https://doi.org/10.1136/bcr-2012-006283>
59. Lee EY, Choi JO, Park HN, Park EJ, Lee GS, Park JY, et al. Malignant melanoma of unknown primary origin presenting as cardiac metastasis. *Korean Circ J*. 2012;42(4):278–80. <http://dx.doi.org/10.4070/kcj.2012.42.4.278>
60. Mesa M, Quesada JL, Pinas J. Metastasis of amelanotic melanoma of unknown origin in the parotid gland. *Br J Oral Maxillofac Surg*. 2009;47(7):569–71. <http://dx.doi.org/10.1016/j.bjoms.2008.10.011>
61. Wilkinson AR, Mahore SD, Bothale KA. A case of metastatic melanoma in the breast with unknown primary site, diagnosed by fine needle aspiration cytology. *Indian J Pathol Microbiol*. 2009;52(4):587–8. <http://dx.doi.org/10.4103/0377-4929.56133>
62. Jain D, Singh T, Kumar N, Daga MK. Metastatic malignant melanoma in bone marrow with occult primary site—A case report with review of literature. *Diagn Pathol*. 2007;2:38. <http://dx.doi.org/10.1186/1746-1596-2-38>
63. de Wilt JH, Farmer SE, Scolyer RA, McCaughan BC, Thompson JF. Isolated melanoma in the lung where there is no known primary site: Metastatic disease or primary lung tumour? *Melanoma Res*. 2005;15(6):531–7. <http://dx.doi.org/10.1097/00008390-200512000-00008>
64. Wagner MS, Shoup M, Pickleman J, Yong S. Primary malignant melanoma of the common bile duct: A case report and review of the literature. *Arch Pathol Lab Med*. 2000;124(3):419–22.
65. Mercer NS, Devaraj VS. Intramuscular metastatic melanoma with an unknown primary. *Br J Plast Surg*. 1990;43(3):367–8. [http://dx.doi.org/10.1016/0007-1226\(90\)90092-E](http://dx.doi.org/10.1016/0007-1226(90)90092-E)
66. Shenoy S, Cassim R. Metastatic melanoma to the gastrointestinal tract: Role of surgery as palliative treatment. *W V Med J*. 2013;109(1):30–3.
67. Kotteas EA, Adamopoulos A, Drogitis PD, Zalonis A, Giannopoulos KV, Karapanagiotou EM, et al. Gastrointestinal bleeding as initial presentation of melanoma of unknown primary origin: Report of a case and review of the literature. *In Vivo*. 2009;23(3):487–9.
68. Shan GD, Xu GQ, Chen LH, Wang ZM, Jin EY, Hu FL, et al. Diffuse liver infiltration by melanoma of unknown primary origin: One case report and literature review. *Intern Med*. 2009;48(24):2093–6. <http://dx.doi.org/10.2169/internalmedicine.48.2542>
69. Basarici I, Demir I, Yilmaz H, Altekin RE. Obstructive metastatic malignant melanoma of the heart: Imminent pulmonary arterial occlusion caused by right ventricular metastasis with unknown origin of the primary tumor. *Heart Lung*. 2006;35(5):351–4. <http://dx.doi.org/10.1016/j.hrtlng.2005.11.001>
70. Kakutani K, Doita M, Nishida K, Miyamoto H, Kurosaka M. Radiculopathy due to malignant melanoma in the sacrum with unknown primary site. *Eur Spine J*. 2008;17(Suppl 2):S271–4. <http://dx.doi.org/10.1007/s00586-007-0561-1>
71. Meng MV, Werboff LH. Hematospermia as the presenting symptom of metastatic malignant melanoma of unknown primary origin. *Urology*. 2000;56(2):330. [http://dx.doi.org/10.1016/S0090-4295\(00\)00634-8](http://dx.doi.org/10.1016/S0090-4295(00)00634-8)
72. Levidou G, Korkolopoulou P, Papetta A, Patsouris E, Agapitos E. Leptomeningeal melanoma of unknown primary site: Two cases with an atypical presentation of acute meningitis. *Clin Neuropathol*. 2007;26(6):299–305. <http://dx.doi.org/10.5414/NPP26299>

73. Primka EJ 3rd, King C, O'Keefe EJ. Malignant melanoma of unknown origin presenting as a systemic vasculitis. *Arch Dermatol.* 1993;129(9):1205–7. <http://dx.doi.org/10.1001/archderm.1993.01680300135029>
74. Palma JA, Martin-Algarra S. Chronic inflammatory demyelinating polyneuropathy associated with metastatic malignant melanoma of unknown primary origin. *J Neurooncol.* 2009;94(2):279–81. <http://dx.doi.org/10.1007/s11060-009-9848-x>
75. Kiratli H, Thirkill CE, Bilgic S, Eldem B, Kececi A. Paraneoplastic retinopathy associated with metastatic cutaneous melanoma of unknown primary site. *Eye (Lond).* 1997;11(Pt 6):889–92. <http://dx.doi.org/10.1038/eye.1997.227>
76. Manganoni AM, Farfaglia R, Sereni E, Farisoglio C, Pavoni L, Calzavara-Pinton PG. Melanoma of unknown primary with nodal metastases, presenting with vitiligo-like depigmentation. *G Ital Dermatol Venereol.* 2012;147(2):210–11.
77. Sexton M, Snyder CR. Generalized melanosis in occult primary melanoma. *J Am Acad Dermatol.* 1989;20(2 Pt 1):261–6. [http://dx.doi.org/10.1016/S0190-9622\(89\)70032-3](http://dx.doi.org/10.1016/S0190-9622(89)70032-3)
78. Zanglis A, Strataki A, Andreopoulos D, Sarafianou E, Baziotis N. Symmetric metastatic melanoma of unknown primary, presenting as Gorham-Stout syndrome. *Hell J Nucl Med.* 2011;14(1):78–80.
79. Cho EA, Lee MA, Kang H, Lee SD, Kim HO, Park YM. Vitiligo-like depigmentation associated with metastatic melanoma of an unknown origin. *Ann Dermatol.* 2009;21(2):178–81. <http://dx.doi.org/10.5021/ad.2009.21.2.178>
80. Ghosh SK, Bandyopadhyay D, Barma KD, Basu S, Roy A. Metastatic melanoma from an unknown primary site presenting as skin-colored nodules and multiple visceral involvement. *Skinmed.* 2012;10(6):396–9.
81. Kumar M, DeBono R, Sommerlad BC. Metastatic malignant melanoma of unknown primary site: A case of a possible primary declaring itself 18 months after the secondaries. *Br J Plast Surg.* 1998;51(3):258–9. <http://dx.doi.org/10.1054/bjps.1997.0275>
82. Eckert F, Baricevic B, Landthaler M, Schmid U. Metastatic signet-ring cell melanoma in a patient with an unknown primary tumor. Histologic, immunohistochemical, and ultrastructural findings. *J Am Acad Dermatol.* 1992;26(5 Pt 2):870–5. [http://dx.doi.org/10.1016/0190-9622\(92\)70126-Z](http://dx.doi.org/10.1016/0190-9622(92)70126-Z)
83. Adler MJ, Beckstead J, White CR Jr. Angiomatoid melanoma: A case of metastatic melanoma mimicking a vascular malignancy. *Am J Dermatopathol.* 1997;19(6):606–9. <http://dx.doi.org/10.1097/00000372-199712000-00010>
84. Schlagenhaupt B, Stroebel W, Ellwanger U, Meier F, Zimmermann C, Breuninger H, et al. Metastatic melanoma of unknown primary origin shows prognostic similarities to regional metastatic melanoma: Recommendations for initial staging examinations. *Cancer.* 1997;80(1):60–5. [http://dx.doi.org/10.1002/\(SICI\)1097-0142\(19970701\)80:1%3C60::AID-CNCR8%3E3.0.CO;2-J](http://dx.doi.org/10.1002/(SICI)1097-0142(19970701)80:1%3C60::AID-CNCR8%3E3.0.CO;2-J)
85. Hughes MC, Wright A, Barbour A, Thomas J, Smithers BM, Green AC, et al. Patients undergoing lymphadenectomy for stage III melanomas of known or unknown primary site do not differ in outcome. *Int J Cancer.* 2013;133(12):3000–7. <http://dx.doi.org/10.1002/ijc.28318>
86. Rutkowski P, Nowecki ZI, Dziewirski W, Zdzienicki M, Pienkowski A, Salamacha M, et al. Melanoma without a detectable primary site with metastases to lymph nodes. *Dermatol Surg.* 2010;36(6):868–76. <http://dx.doi.org/10.1111/j.1524-4725.2010.01562.x>
87. Baab GH, McBride CM. Malignant melanoma: The patient with an unknown site of primary origin. *Arch Surg.* 1975;110(8):896–900. <http://dx.doi.org/10.1001/archsurg.1975.01360140040008>
88. Jonk A, Kroon BB, Rumke P, Mooi WJ, Hart AA, van Dongen JA. Lymph node metastasis from melanoma with an unknown primary site. *Br J Surg.* 1990;77(6):665–8. <http://dx.doi.org/10.1002/bjs.1800770625>
89. Balch CM, Gershenwald JE, Soong SJ, Thompson JF, Atkins MB, Byrd DR, et al. Final version of 2009 AJCC melanoma staging and classification. *J Clin Oncol.* 2009;27(36):6199–206. <http://dx.doi.org/10.1200/JCO.2009.23.4799>
90. Oberholzer PA, Urosevic M, Steinert HC, Dummer R. Baseline staging of melanoma with unknown primary site: The value of serum s100 protein and positron emission tomography. *Dermatology.* 2008;217(4):351–5. <http://dx.doi.org/10.1159/000155878>
91. Pfeil AF, Leiter U, Buettner PG, Eigentler TK, Weide B, Meier F, et al. Melanoma of unknown primary is correctly classified by the AJCC melanoma classification from 2009. *Melanoma Res.* 2011;21(3):228–34. <http://dx.doi.org/10.1097/CMR.0b013e32834577ec>

92. de Waal AC, Aben KK, van Rossum MM, Kiemeneij LA. Melanoma of unknown primary origin: A population-based study in the Netherlands. *Eur J Cancer*. 2013;49(3):676–83. <http://dx.doi.org/10.1016/j.ejca.2012.09.005>
93. Milton GW, Shaw HM, McCarthy WH. Occult primary malignant melanoma: Factors influencing survival. *Br J Surg*. 1977;64(11):805–8. <http://dx.doi.org/10.1002/bjcs.1800641114>
94. Nasri S, Namazie A, Dulguerov P, Mickel R. Malignant melanoma of cervical and parotid lymph nodes with an unknown primary site. *Laryngoscope*. 1994;104(10):1194–8. <http://dx.doi.org/10.1288/00005537-199410000-00002>
95. Katz KA, Jonasch E, Hodi FS, Soiffer R, Kwitkiwski K, Sober AJ, et al. Melanoma of unknown primary: Experience at Massachusetts General Hospital and Dana-Farber Cancer Institute. *Melanoma Res*. 2005;15(1):77–82. <http://dx.doi.org/10.1097/00008390-200502000-00013>
96. Weide B, Faller C, Buttner P, Pflugfelder A, Leiter U, Eigentler TK, et al. Prognostic factors of melanoma patients with satellite or in-transit metastasis at the time of stage III diagnosis. *PLoS One*. 2013;8(4):e63137. <http://dx.doi.org/10.1371/journal.pone.0063137>
97. Weide B, Faller C, Elsasser M, Buttner P, Pflugfelder A, Leiter U, et al. Melanoma patients with unknown primary site or nodal recurrence after initial diagnosis have a favourable survival compared to those with synchronous lymph node metastasis and primary tumour. *PLoS One*. 2013;8(6):e66953. <http://dx.doi.org/10.1371/journal.pone.0066953>
98. Quaglino P, Marengo F, Osella-Abate S, Cappello N, Ortoncelli M, Salomone B, et al. Vitiligo is an independent favourable prognostic factor in stage III and IV metastatic melanoma patients: Results from a single-institution hospital-based observational cohort study. *Ann Oncol*. 2010;21(2):409–14. <http://dx.doi.org/10.1093/annonc/mdp325>
99. Duhra P, Ilchyshyn A. Prolonged survival in metastatic malignant melanoma associated with vitiligo. *Clin Exp Dermatol*. 1991;16(4):303–5. <http://dx.doi.org/10.1111/j.1365-2230.1991.tb00383.x>
100. Reintgen DS, McCarty KS, Woodard B, Cox E, Seigler HF. Metastatic malignant melanoma with an unknown primary. *Surg Gynecol Obstet*. 1983;156(3):335–40.
101. Velez A, Walsh D, Karakousis CP. Treatment of unknown primary melanoma. *Cancer*. 1991; 68(12):2579–81. [http://dx.doi.org/10.1002/1097-0142\(19911215\)68:12%3C2579::AID-CNCR2820681209%3E3.0.CO;2-G](http://dx.doi.org/10.1002/1097-0142(19911215)68:12%3C2579::AID-CNCR2820681209%3E3.0.CO;2-G)
102. Chang P, Knapper WH. Metastatic melanoma of unknown primary. *Cancer*. 1982;49(6):1106–11. [http://dx.doi.org/10.1002/1097-0142\(19820315\)49:6%3C1106::AID-CNCR2820490607%3E3.0.CO;2-0](http://dx.doi.org/10.1002/1097-0142(19820315)49:6%3C1106::AID-CNCR2820490607%3E3.0.CO;2-0)
103. Santini H, Byers RM, Wolf PF. Melanoma metastatic to cervical and parotid nodes from an unknown primary site. *Am J Surg*. 1985;150(4):510–12. [http://dx.doi.org/10.1016/0002-9610\(85\)90165-5](http://dx.doi.org/10.1016/0002-9610(85)90165-5)
104. Vijuk G, Coates AS. Survival of patients with visceral metastatic melanoma from an occult primary lesion: A retrospective matched cohort study. *Ann Oncol*. 1998;9(4):419–22. <http://dx.doi.org/10.1023/A:1008201931959>
105. Prens SP, van der Ploeg AP, van Akkooi AC, van Montfort CA, van Geel AN, de Wilt JH, et al. Outcome after therapeutic lymph node dissection in patients with unknown primary melanoma site. *Ann Surg Oncol*. 2011;18(13):3586–92. <http://dx.doi.org/10.1245/s10434-011-1801-5>
106. Kuk D, Shoushtari AN, Barker CA, Panageas KS, Munhoz RR, Momtaz P, et al. Prognosis of mucosal, uveal, acral, nonacral cutaneous, and unknown primary melanoma from the time of first metastasis. *Oncologist*. 2016;21(7):848–54. <http://dx.doi.org/10.1634/theoncologist.2015-0522>
107. Bae JM, Choi YY, Kim DS, Lee JH, Jang HS, Lee JH, et al. Metastatic melanomas of unknown primary show better prognosis than those of known primary: A systematic review and meta-analysis of observational studies. *J Am Acad Dermatol*. 2015;72(1):59–70. <http://dx.doi.org/10.1016/j.jaad.2014.09.029>
108. Tos T, Klyver H, Drzewiecki KT. Extensive screening for primary tumor is redundant in melanoma of unknown primary. *J Surg Oncol*. 2011;104(7):724–7. <http://dx.doi.org/10.1002/jso.21994>
109. Ribero S, Pampena R, Bataille V, Moscarella E, Thomas L, Quaglino P, et al. Unknown primary melanoma: Worldwide Survey on Clinical Management. *Dermatology*. 2016;232(6):704–7. <http://dx.doi.org/10.1159/000453592>
110. Galli F, Petraitiene V, Muthu SK, James S, Koppa VR, Arya A. Challenges in the differential diagnosis of interdigitating dendritic cell sarcoma of intraparotid lymph node vs. metastatic

- malignant melanoma with unknown primary site. *Int J Surg Pathol.* 2015;23(3):248–52. <http://dx.doi.org/10.1177/1066896914567333>
111. Biernacka A, Linos KD, DeLong PA, Suriawinata AA, Padmanabhan V, Liu X. A case of S-100 negative melanoma: A diagnostic pitfall in the workup of a poorly differentiated metastatic tumor of unknown origin. *Cytojournal.* 2016;13:21. <http://dx.doi.org/10.4103/1742-6413.190914>
 112. Azoury SC, Crompton JG, Straughan DM, Klemen ND, Reardon ES, Beresnev TH, et al. Unknown primary nasopharyngeal melanoma presenting as severe recurrent epistaxis and hearing loss following treatment and remission of metastatic disease: A case report and literature review. *Int J Surg Case Rep.* 2015;10:232–5. <http://dx.doi.org/10.1016/j.ijscr.2015.03.053>
 113. Sciacca V, Ciorra AA, Di Fonzo C, Rossi R, Pistillucci G, Lugini A, et al. Long-term survival of metastatic melanoma to the ileum with evidence of primary cutaneous disease after 15 years of follow-up: A case report. *Tumori.* 2010;96(4):640–3.
 114. Greco FA, Spigel DR, Yardley DA, Erlander MG, Ma XJ, Hainsworth JD. Molecular profiling in unknown primary cancer: Accuracy of tissue of origin prediction. *Oncologist.* 2010;15(5):500–6. <http://dx.doi.org/10.1634/theoncologist.2009-0328>
 115. de Giorgi V, Stante M, Carli P. Unknown primary melanoma. *Eur J Cancer.* 2004;40(9):1454–5. <http://dx.doi.org/10.1016/j.ejca.2004.02.017>
 116. Dalal MD, Morgans CW, Duvoisin RM, Gamboa EA, Jeffrey BG, Garg SJ, et al. Diagnosis of occult melanoma using transient receptor potential melastatin 1 (TRPM1) autoantibody testing: A novel approach. *Ophthalmology.* 2013;120(12):2560–4. <http://dx.doi.org/10.1016/j.ophtha.2013.07.037>
 117. Stante M, de Giorgi V, Carli P. Possible role of dermoscopy in the detection of a primary cutaneous melanoma of unknown origin. *J Eur Acad Dermatol Venereol.* 2006;20(3):299–302. <http://dx.doi.org/10.1111/j.1468-3083.2006.01355.x>
 118. Klausner JM, Gutman M, Inbar M, Rozin RR. Unknown primary melanoma. *J Surg Oncol.* 1983;24(2):129–31. <http://dx.doi.org/10.1002/jso.2930240213>
 119. Lee CC, Faries MB, Morton DL. Management decisions for nodal metastasis from an unknown primary melanoma. *Am J Hematol Oncol.* 2008;7(7):306–8.
 120. van Beek EJ, Balm AJ, Nieweg OE, Hamming-Vrieze O, Lohuis PJ, Klop WM. Treatment of regional metastatic melanoma of unknown primary origin. *Cancers (Basel).* 2015;7(3):1543–53. <http://dx.doi.org/10.3390/cancers7030849>
 121. van der Ploeg AP, Haydu LE, Spillane AJ, Scolyer RA, Quinn MJ, Saw RP, et al. Melanoma patients with an unknown primary tumor site have a better outcome than those with a known primary following therapeutic lymph node dissection for macroscopic (clinically palpable) nodal disease. *Ann Surg Oncol.* 2014;21(9):3108–16. <http://dx.doi.org/10.1245/s10434-014-3679-5>
 122. O'Neill JK, Khundar R, Knowles L, Scott-Young N, Orlando A. Melanoma with an unknown primary—A case series. *J Plast Reconstr Aesthet Surg.* 2010;63(12):2071–80. <http://dx.doi.org/10.1016/j.bjps.2010.02.028>
 123. Kelly J, Redmond HP. Melanoma of unknown origin: A case series. *Ir J Med Sci.* 2010;179(4):629–32. <http://dx.doi.org/10.1007/s11845-009-0405-6>