

Chapter 18

Seminal Vesicles in Autosomal Dominant Polycystic Kidney Disease

Jin Ah Kim¹, Jon D. Blumenfeld^{2,3}, Martin R. Prince¹

¹Department of Radiology, Weill Cornell Medical College & New York Presbyterian Hospital, New York, USA; ²The Rogosin Institute, New York, USA; ³Department of Medicine, Weill Cornell Medical College, New York, USA

Author for Correspondence: Jin Ah Kim MD, Department of Radiology, Weill Cornell Medical College & New York Presbyterian Hospital, New York, USA.
Email: jik2008@nyp.org

Doi: <http://dx.doi.org/10.15586/codon.pkd.2015.ch18>

Copyright: The Authors.

Licence: This open access article is licenced under Creative Commons Attribution 4.0 International (CC BY 4.0). <http://creativecommons.org/licenses/by/4.0/>
Users are allowed to share (copy and redistribute the material in any medium or format) and adapt (remix, transform, and build upon the material for any purpose, even commercially), as long as the author and the publisher are explicitly identified and properly acknowledged as the original source.



Abstract

Extra-renal manifestations of autosomal dominant polycystic kidney disease (ADPKD) have been known to involve male reproductive organs, including cysts in testis, epididymis, seminal vesicles, and prostate. The reported prevalence of seminal vesicle cysts in patients with ADPKD varies widely, from 6% by computed tomography (CT) to 21%–60% by transrectal ultrasonography. However, seminal vesicles in ADPKD that are dilated, with a diameter greater than 10 mm by magnetic resonance imaging (MRI), are

In: *Polycystic Kidney Disease*. Xiaogang Li (Editor)
ISBN: 978-0-9944381-0-2; Doi: <http://dx.doi.org/10.15586/codon.pkd.2015>
Codon Publications, Brisbane, Australia.

Kim et al.

“megavesicles”. This is a separate entity from seminal vesicle cysts and has a prevalence of 23% in ADPKD patients, but is not known to occur in patients without ADPKD. The basis of these cystic changes and megavesicles has not been established, but may be explained by an imbalance between cell growth/proliferation inhibitors and stimulators analogous to mechanisms in renal tubular epithelial cells, hepatic ducts, and in the vasculature. Male infertility has been associated with ADPKD, although a causal role of seminal tract abnormalities has not been established. In this chapter, the anatomic abnormalities of seminal vesicles in ADPKD and their clinical significance will be discussed.

Key Words: Autosomal dominant polycystic kidney disease; Megavesicles; Seminal vesicles; Seminal vesicle cysts

Introduction

Autosomal dominant polycystic kidneys disease (ADPKD) is the most common inherited kidney disease and is the fourth most common cause of end stage kidney disease. Extra-renal manifestations are prevalent, including cysts in liver, pancreas, spleen, and intracranial saccular aneurysms (1-3). Mutations in *PKD1* and *PKD2* genes are known to cause ADPKD, with *PKD1* mutations accounting for 75%-85% of cases. Polycystin-1 and polycystin-2 are integral membrane proteins encoded by the *PKD1* and *PKD2* genes, respectively. Our understanding of the role of these proteins in normal physiology and in the pathophysiology of ADPKD is evolving (2-4).

Few studies have evaluated ADPKD manifestations in the male reproductive system. These include case reports and studies reporting cystic changes in the seminal vesicles, including reports focused on infertility (5-19). This review will highlight seminal vesicle abnormalities in ADPKD.

Seminal vesicles

The seminal vesicles are a pair of glands positioned posterior and inferior to the urinary bladder, and lateral to the vas deferens. Each vesicle consists of a single tube coiled on itself and joined to the distal portion of the vas deferens (ductus deferens) which becomes the ejaculatory duct. The two ejaculatory ducts immediately pass through the prostate gland to open separately into the verumontanum of the prostatic urethra (Figure 1).

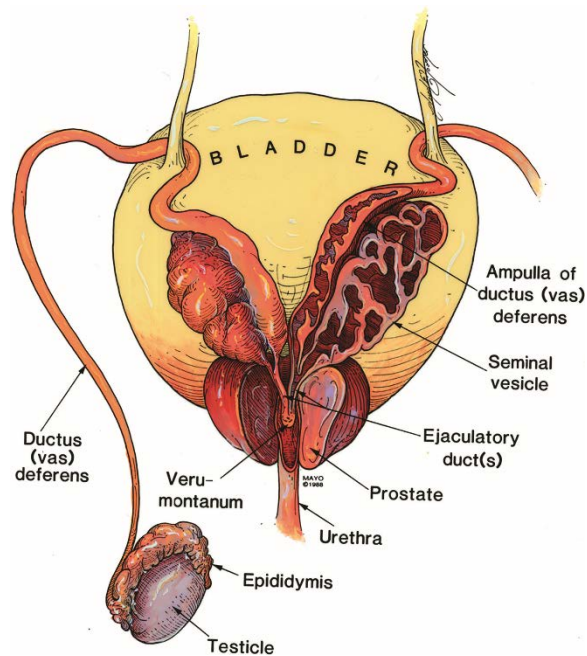


Figure 1. Posterior view of male urogenital organs including the seminal vesicles, vasa deferens, and ejaculatory ducts (Image purchased from the original copyright holder; 21).

The seminal vesicles produce and secrete seminal fluid, which consists of 50-80% of the ejaculate volume. The normal seminal vesicles are tortuous tubular fluid-containing structures with thin septa identified by ultrasonography (US), computed tomography (CT), and magnetic resonance imaging (MRI) (Figure 2). US is commonly used as initial choice of evaluation, whereas MRI is used for more complex cases. The normal mean seminal vesicle diameter is 1.5 ± 0.4 cm (by CT) (20, 21) or 0.9 ± 0.3 cm (by US) (22), and about 3.1 ± 0.5 cm in length (by CT) (21).

Anatomic abnormalities of seminal vesicles in ADPKD patients

Seminal vesicle cysts

Seminal vesicle cysts can be acquired or congenital. Acquired seminal vesicle cysts occur in the general population and are thought to be due to post-infection fibrosis or compression of the ejaculatory ducts related to obstructive causes (23). Congenital seminal vesicle cysts may occur as an isolated finding, but are predominantly associated with urogenital

anomalies, such as ipsilateral renal agenesis or dysgenesis, ectopic ureteral insertion, and vas deferens agenesis (21, 24, 25). Most studies of ADPKD patients reported bilateral seminal vesicle cysts (6-8, 17), although it is uncertain whether these cysts were acquired or congenital.

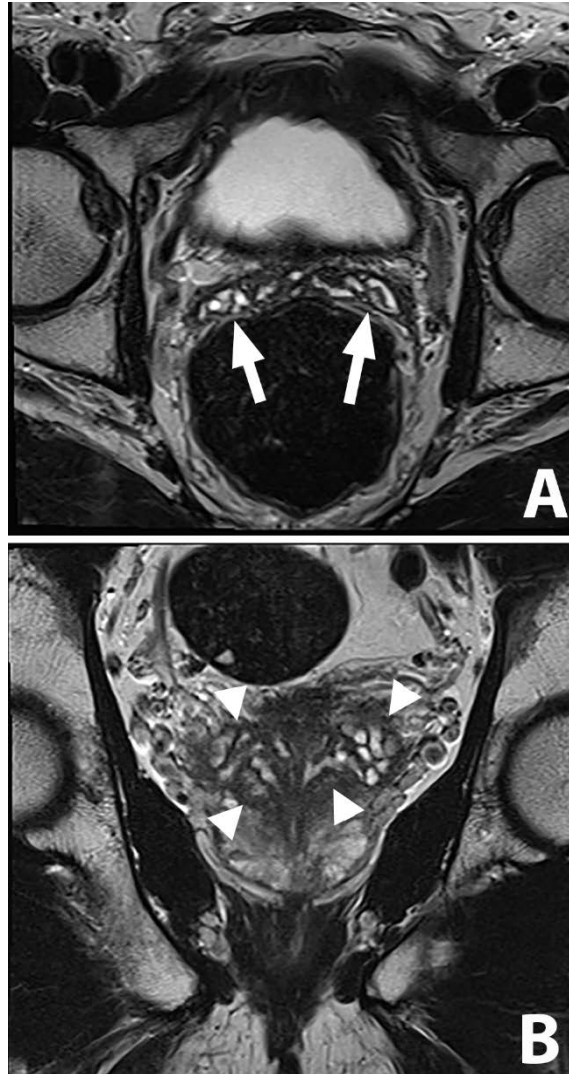


Figure 2. MR imaging appearance of normal seminal vesicles. Figure 2A. Axial T2-weighted image demonstrating tubular structures (arrows) with septae, representing normal seminal vesicles, posterior to the urine-filled bladder. Figure 2B. Coronal T2-weighted image showing seminal vesicles (arrowheads). Prostate gland is partly visualized inferior to the seminal vesicles.

Seminal Vesicles in ADPKD

The reported prevalence of seminal vesicle cysts in ADPKD patients varies widely using different imaging modalities; from 6% by CT (5), to 21% to 60% by transrectal US (6, 7, 17). However, the reported prevalence is 5.2% by transrectal US in the general population without ADPKD (26). Seminal vesicle cysts were identified by US as discrete anechoic areas (simple cysts) or hypoechoic areas containing internal echoes (hypoechoic cysts), measuring greater than 5 mm in diameter (6, 7, 17).

In a prospective study of ADPKD patients, Belet et al. reported a seminal vesicle cyst prevalence of 39% (41 out of 104 patients) using US studies (abdominal, transrectal, and scrotal); the prevalence was 2% in non-ADPKD controls (1 of 62 patients); $p < 0.01$ matched for age, level of renal function, and renal replacement therapy (6). Reproductive tract cysts were identified during evaluation of primary infertility (5%) or were found incidentally. In that study, 76% of the cysts were anechoic (simple) and 24% were hyperechoic. Cysts in the other regions of the reproductive tract were also identified in the 41 patients with seminal vesicle cysts; epididymal cysts were found in 20%, and prostatic cysts in 15%. There was no association of seminal vesicle cysts with cysts in the liver, epididymis, prostate, patient age or serum creatinine level.

In another prospective study of 28 ADPKD patients (age 18-50 years with estimated GFR > 60 ml/min/1.73 m²), Torra et al. reported seminal tract cysts in 10 patients (35.7%) and seminal vesicle cysts in 21%, using transrectal US (17). Eight patients (28.6%) in that study were being evaluated for infertility.

In a study of 45 ADPKD patients with a mean age 40 years, Danaci, et al. found the prevalence of seminal vesicle cysts to be 60%. None of the control subjects, who were matched for age, renal function, and renal replacement therapy, had seminal vesicle cysts (8). This study suggested that seminal vesicle cysts may develop later in life, based on their findings of a positive correlation between seminal vesicle cysts, hepatic cysts and serum creatinine concentrations. However no significant relationship between the presence of seminal vesicle cysts and the age of the patients was identified.

Seminal vesicle ectasia

Seminal vesicle cysts are the most commonly reported finding in the reproductive system of ADPKD patients (6-8, 17). However, seminal vesicle ectasia is a separate entity, which can be mistaken for cysts on US and other imaging modalities (14, 16-18). Dilatation of seminal vesicles has been demonstrated on ejaculatory ductograms (16). "Megavesicle" is defined as asymmetric or bilateral diffuse enlargement of anteroposterior dimension exceeding 1.0 cm, without isolated cysts or septa (Figure 3 and Figure 4). This entity must be distinguished

from seminal vesicle cysts, which are defined as isolated cysts adjacent to normal-diameter remaining parts of the seminal vesicles.

In a retrospective case-control study, Joo et al. compared the size of seminal vesicles in 68 ADPKD patients and 68 controls, matched for age using 3D CT (11). The mean diameter of seminal vesicles in the ADPKD group was significantly larger than the controls (axial: 1.70 vs 1.53 cm, $p=0.01$; coronal: 1.86 vs 1.68 cm, $p=0.02$); the diameter decreased with age in controls, but there was no association with age in the ADPKD group in this or other studies (11, 27). Interpretation of this study was limited by the absence of clinical information, including level of kidney function and prevalence of infertility.

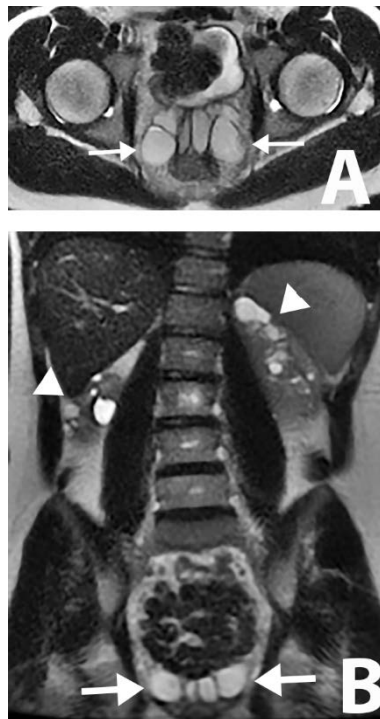


Figure 3. An example of abnormal seminal vesicles. A 19 year old male, diagnosed with ADPKD on ultrasound, without family history. Bilaterally dilated hyperintense seminal vesicles on single shot fast spin echo (SSFSE) images (axial and coronal images) on 1.5 T MR, measuring 1.9 cm on the left and 2.1 cm on the right. No reproductive symptom was reported at the time of imaging and no fertility evaluation was performed. Normal serum creatinine. A, Axial SSFSE image; B, Coronal SSFSE image, demonstrating dilated both seminal vesicles (arrows) and multiple cysts in both kidneys (arrowheads).

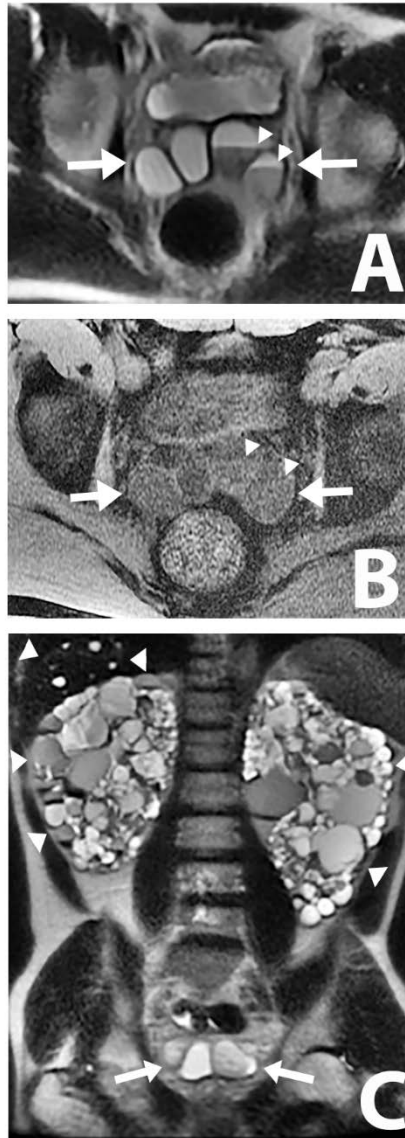


Figure 4. An example of abnormal seminal vesicles. A 47 year old male, with family history of ADPKD presenting with gross hematuria. Bilateral seminal vesicles are dilated measuring 3 cm, each with fluid level within the left seminal vesicle, possibly representing hematospermia. The patient has children. A, Axial SSFSE image; B, Axial T1 weighted LAVA image demonstrating high signal intensity fluid level in the left seminal vesicle, representing hematospermia; 4C, Coronal SSFSE image, demonstrating dilated seminal vesicles (arrows) as well as multiple cysts in the liver and kidneys (arrowheads).

Kim et al.

Reig et al. reported a greater mean seminal vesicle diameter, measured by MRI, in ADPKD patients than in controls (4.2 mm vs 3.1 mm; $p < 0.0001$) (15). Moreover, in that study, the prevalence of megavesicles was 23% when a partition value of 1 cm diameter was used, and 15% when the partition value was 1.5 cm diameter. Dilated seminal vesicles can also rarely be found in patients without ADPKD, usually due to obstruction, which may be related to urogenital anomalies or calculi. These patients can present with hematospermia (14, 28, 29).

Megavesicles in ADPKD are reportedly not caused by obstruction (10). Hendry et al. identified free flow of dye in the ejaculatory duct on the percutaneous vesiculography, as well as free efflux of dye from the vesicles during surgery. The presence of sperm in the aspirate from the vesicle, and lack of improvement after ductal ostia resection in 3 of 4 patients, supports a nonobstructive cause of the megavesicles. Hendry et al. suggested that the underlying problem may be failure of propulsion of the contents within the seminal vesicles and ampullary parts of the vasa, rather than mechanical obstruction (10).

Although most of studies report a high prevalence of seminal vesicle cysts (up to 60%) in ADPKD, a large fraction of those cysts may actually be megavesicles that resemble cysts by ultrasonography (9, 10, 15). The advantages of dynamic study by vesiculography and superior soft tissue contrast MRI have likely resulted in the higher detection of megavesicles in the ADPKD population (Figures 2 and 3).

Clinical significance and infertility

Patients with ADPKD are generally known to be fertile, although there are several reports of male infertility in ADPKD. Torra et al. found that 28.5% of 28 ADPKD patients complained of infertility (17). This is a higher prevalence than in the general population, which is estimated as 15% in couples and 7% in men in western countries. However, Belet et al. reported only 5% prevalence of infertility in a prospective study of 104 ADPKD patients based on patient interviews, which was a larger ADPKD patient group than that reported by Torra et al. (6).

Included among the potential etiologies of male infertility in ADPKD are: (i) uremia; (ii) necrospermia (low sperm motility with high proportion of dead sperm); (iii) immotile sperm that have been attributed in some cases to ultrastructural flagellar defects caused by abnormal polycystins; (iv) seminal vesicle cysts; and (v) ejaculatory duct cysts (6, 17-19, 30).

Seminal Vesicles in ADPKD

There are few studies of infertility and seminal vesicle abnormalities in ADPKD patients (6, 9, 10, 12, 17, 31). Belet et al. noted presence of delayed liquefaction and hyperviscosity in one semen analysis of an infertile patient, and suggested that the seminal vesicle cyst formation caused infertility (6). Hendry et al. proposed that failure of seminal vesicles to contract effectively caused megavesicles and eventually led to decreased ejaculate volume (10). Fang et al. reviewed data obtained from 4,108 infertile men for necrospemia and found 20.7% of the infertile patients with necrospemia had ADPKD (9), with one case demonstrating dilated seminal vesicles by US. They speculated that necrospemia in ADPKD may result from stasis of the seminal tract content due to functional obstruction, and subsequent sperm death and degeneration (9).

Torra et al. reported prevalence of semen abnormalities and cysts in the seminal tract (17). A semen analysis, performed on 28 ADPKD patients, showed abnormalities in 91% and decreased seminal volume in 30% of ADPKD patients. Although decreased seminal volume may be related to distal seminal tract obstruction due to extrinsic compression by seminal vesicle cysts or an abnormality within seminal vesicles, no significant association between seminal tract cysts and semen abnormality was noted in that study. Torra et al. suggested that the presence of seminal tract cysts likely has limited, if any, clinical consequences, given the relatively high prevalence of seminal tract cysts and the relatively low frequency of infertility in ADPKD (17).

The most common semen abnormality in the study by Torra et al. was asthenozoospermia (reduced sperm motility) (7). When compared to semen donors without ADPKD, the percentage of progressive motile forms was the only significant difference ($p < 0.0001$) (17). This suggests that an abnormality in polycystins in ADPKD which play a role in the abnormal structure of the cilia or flagella may affect sperm motility (12, 17, 31).

Summary and conclusion

ADPKD is associated with cystic dilatation and ectasia of seminal vesicles. The pathogenesis of these abnormal findings and their relation to infertility is controversial. Prospective, controlled studies of the male reproductive tract and sperm ultrastructure and functional characteristics are required to define the prevalence and mechanisms of infertility in men with ADPKD.

Conflict of interest

The authors declare that they have no conflicts of interest with respect to research, authorship and/or publication of this book chapter.

Acknowledgement

Supported in part by grant # UL1RR024143 from the National Center for Advancing Translational Sciences (NCATS), National Institutes of Health."

References

1. Chapman AB, Devuyst O, Eckardt KU, Gansevoort RT, Harris T, Horie S, et al. Autosomal-dominant polycystic kidney disease (ADPKD): executive summary from a Kidney Disease: Improving Global Outcomes (KDIGO) Controversies Conference. *Kidney Int.* 2015;88(1):17-27.
<http://dx.doi.org/10.1038/ki.2015.59>
PMid:25786098
2. Torres VE, Harris PC. Autosomal dominant polycystic kidney disease: the last 3 years. *Kidney Int.* 2009;76(2):149-68.
<http://dx.doi.org/10.1038/ki.2009.128>
PMid:19455193 PMCID:PMC2812475
3. Torres VE, Harris PC, Pirson Y. Autosomal dominant polycystic kidney disease. *Lancet.* 2007;369(9569):1287-301.
[http://dx.doi.org/10.1016/S0140-6736\(07\)60601-1](http://dx.doi.org/10.1016/S0140-6736(07)60601-1)
4. Ong AC, Harris PC. A polycystin-centric view of cyst formation and disease: the polycystins revisited. *Kidney Int.* 2015.
<http://dx.doi.org/10.1038/ki.2015.207>
PMid:26200945
5. Alpern MB, Dorfman RE, Gross BH, Gottlieb CA, Sandler MA. Seminal vesicle cysts: association with adult polycystic kidney disease. *Radiology.* 1991;180(1):79-80.
<http://dx.doi.org/10.1148/radiology.180.1.2052727>
PMid:2052727
6. Belet U, Danaci M, Sarikaya S, Odabas F, Utas C, Tokgoz B, et al. Prevalence of epididymal, seminal vesicle, prostate, and testicular cysts in autosomal dominant polycystic kidney disease. *Urology.* 2002;60(1):138-41.
[http://dx.doi.org/10.1016/S0090-4295\(02\)01612-6](http://dx.doi.org/10.1016/S0090-4295(02)01612-6)

7. Danaci M, Akpolat T, Bastemir M, Akan H, Selcuk M. Seminal vesicle cysts in the patients with adult polycystic kidney disease. *Clin Nephrol.* 1998;50(3):199-200. PMID:9776429
8. Danaci M, Akpolat T, Bastemir M, Sarikaya S, Akan H, Selcuk MB, et al. The prevalence of seminal vesicle cysts in autosomal dominant polycystic kidney disease. *Nephrol Dial Transplant.* 1998;13(11):2825-8. <http://dx.doi.org/10.1093/ndt/13.11.2825>
9. Fang S, Baker HW. Male infertility and adult polycystic kidney disease are associated with necrospermia. *Fertil Steril.* 2003;79(3):643-4. [http://dx.doi.org/10.1016/S0015-0282\(02\)04759-3](http://dx.doi.org/10.1016/S0015-0282(02)04759-3)
10. Hendry WF, Rickards D, Pryor JP, Baker LR. Seminal megavesicles with adult polycystic kidney disease. *Hum Reprod.* 1998;13(6):1567-9. <http://dx.doi.org/10.1093/humrep/13.6.1567> PMID:9688393
11. Joo I, Kim SH, Cho JY. A comparison of seminal vesicle size on CT between autosomal dominant polycystic kidney disease (ADPKD) patients and normal subjects. *Acta radiologica.* 2010;51(5):569-72. <http://dx.doi.org/10.3109/02841851003652583> PMID:20235741
12. Kierszenbaum AL. Polycystins: what polycystic kidney disease tells us about sperm. *Mol Reprod Dev.* 2004;67(4):385-8. <http://dx.doi.org/10.1002/mrd.20042> PMID:14991728
13. Orhan I, Onur R, Ergin E, Koksall IT, Kadioglu A. Infertility treatment in autosomal dominant polycystic kidney disease (ADPKD)--a case report. *Andrologia.* 2000;32(2):91-3. <http://dx.doi.org/10.1046/j.1439-0272.2000.00335.x> PMID:10755191
14. Pryor JP, Hendry WF. Ejaculatory duct obstruction in subfertile males: analysis of 87 patients. *Fertil Steril.* 1991;56(4):725-30. PMID:1915949
15. Reig B, Blumenfeld J, Donahue S, Prince MR. Seminal megavesicle in autosomal dominant polycystic kidney disease. *Clin Imaging.* 2015;39(2):289-92. <http://dx.doi.org/10.1016/j.clinimag.2014.10.016> PMID:25542752
16. Shefi S, Levron J, Nadu A, Raviv G. Male infertility associated with adult dominant polycystic kidney disease: a case series. *Arch Gynecol Obstet.* 2009;280(3):457-60. <http://dx.doi.org/10.1007/s00404-008-0916-9> PMID:19137444

17. Torra R, Sarquella J, Calabia J, Marti J, Ars E, Fernandez-Llama P, et al. Prevalence of cysts in seminal tract and abnormal semen parameters in patients with autosomal dominant polycystic kidney disease. *Clin J Am Soc Nephrol.* 2008;3(3):790-3.
<http://dx.doi.org/10.2215/CJN.05311107>
PMid:18322042 PMCid:PMC2386699
18. van der Linden EF, Bartelink AK, Ike BW, van Leeuwen B. Polycystic kidney disease and infertility. *Fertil Steril.* 1995;64(1):202-3.
PMid:7789562
19. Vora N, Perrone R, Bianchi DW. Reproductive issues for adults with autosomal dominant polycystic kidney disease. *Am J Kidney Dis.* 2008;51(2):307-18.
<http://dx.doi.org/10.1053/j.ajkd.2007.09.010>
PMid:18215709
20. Silverman PM, Dunnick NR, Ford KK. Computed tomography of the normal seminal vesicles. *Comput Radiol: official journal of the Computerized Tomography Society.* 1985;9(6):379-85.
[http://dx.doi.org/10.1016/0730-4862\(85\)90126-X](http://dx.doi.org/10.1016/0730-4862(85)90126-X)
21. Kim B, Kawashima A, Ryu JA, Takahashi N, Hartman RP, King BF, Jr. Imaging of the seminal vesicle and vas deferens. *Radiographics. Inc.* 2009;29(4):1105-21.
<http://dx.doi.org/10.1148/rg.294085235>
PMid:19605659
22. Hoekstra TH SC, Jaffe T, Hu J, Scherefred L, Khan M, et al. Ultrasound evaluation of seminal vesicle size and the effect of ejaculatory duct cysts. *Fertil Steril.* 1997;68:S35-S6.
[http://dx.doi.org/10.1016/S0015-0282\(97\)90702-0](http://dx.doi.org/10.1016/S0015-0282(97)90702-0)
23. Geveno PA, Van Sinoy ML, Sintzoff SA, Jr., Stallenberg B, Salmon I, Van Regemorter G, et al. Cysts of the prostate and seminal vesicles: MR imaging findings in 11 cases. *AJR Am J Roentgenol.* 1990;155(5):1021-4.
<http://dx.doi.org/10.2214/ajr.155.5.2120929>
PMid:2120929
24. Arora SS, Breiman RS, Webb EM, Westphalen AC, Yeh BM, Coakley FV. CT and MRI of congenital anomalies of the seminal vesicles. *AJR Am J Roentgenol.* 2007;189(1):130-5.
<http://dx.doi.org/10.2214/AJR.06.1345>
PMid:17579162
25. King BF, Hattery RR, Lieber MM, Williamson B, Jr., Hartman GW, Berquist TH. Seminal vesicle imaging. *Radiographics.* 1989;9(4):653-76.
<http://dx.doi.org/10.1148/radiographics.9.4.2667051>
PMid:2667051

Seminal Vesicles in ADPKD

26. Behre HM, Kliesch S, Schadel F, Nieschlag E. Clinical relevance of scrotal and transrectal ultrasonography in andrological patients. *Int J Androl.* 1995;18 Suppl 2:27-31.
PMid:8719855
27. Hayakawa T, Naya Y, Kojima M. Significant changes in volume of seminal vesicles as determined by transrectal sonography in relation to age and benign prostatic hyperplasia. *Tohoku J Exp Med.* 1998;186(3):193-204.
<http://dx.doi.org/10.1620/tjem.186.193>
PMid:10348215
28. Lencioni R, Ortori S, Cioni D, Morelli G, Ceretti E, Cosottini M, et al. Endorectal coil MR imaging findings in hemospermia. *Magma.* 1999;8(2):91-7.
<http://dx.doi.org/10.1007/BF02590525>
PMid:10456371
29. Maeda H, Toyooka N, Kinukawa T, Hattori R, Furukawa T. Magnetic resonance images of hematospermia. *Urology.* 1993;41(5):499-504.
[http://dx.doi.org/10.1016/0090-4295\(93\)90519-G](http://dx.doi.org/10.1016/0090-4295(93)90519-G)
30. Saeki H, Kondo S, Morita T, Sasagawa I, Ishizuka G, Koizumi Y. Immotile cilia syndrome associated with polycystic kidney. *J Urol.* 1984;132(6):1165-6.
PMid:6502812
31. Wagner CA. News from the cyst: insights into polycystic kidney disease. *J Nephrol.* 2008;21(1):14-6.
PMid:18264930